Skeletal Radiology
https://doi.org/10.1007/s00256-019-03352-4

SCIENTIFIC ARTICLE

Tears in the distal superficial medial collateral ligament: the wave sign and other associated MRI findings

Robert D. Boutin[1] · Russell C. Fritz[2] · Richard E. A. Walker[3] · Mini N. Pathria[4] · Richard A. Marder[5] · Lawrence Yao[6]

Received: 4 September 2019 / Revised: 13 November 2019 / Accepted: 14 November 2019

Abstract

Objective To analyze the MRI characteristics of distal superficial medial collateral ligament (sMCL) tears and to identify features of tears displaced superficial to the pes anserinus (Stener-like lesion (SLL)).

Materials and methods Knee MRI examinations at four institutions were selected which showed tears of the sMCL located distal to the joint line. MRIs were evaluated for a SLL, a wavy contour to the sMCL, and the location of the proximal sMCL stump. Additional coexistent knee injuries were recorded.

Results The study included 51 patients (mean age, 28 years [sd, 12]). A SLL was identified in 20 of 51 cases. The proximal stump margin was located significantly ($p < 0.01$) more distal and more medial with a SLL (mean = 33 mm [sd = 11 mm] and mean = 6.5 mm [sd = 2.5 mm], respectively), than without a SLL (mean = 19 mm [sd = 16 mm] and mean = 4.8 mm [sd = 2.4 mm], respectively). Medial compartment osseous injury was significantly ($p < 0.05$) more common with a SLL (75%) than without a SLL (42%). The frequency of concomitant injuries in the group (ACL tear, 82%; PCL tear, 22%; deep MCL tear, 61%; lateral compartment osseous injury, 94%) did not differ significantly between patients with and without a SLL.

Conclusion A distal sMCL tear should be considered when MRI depicts a wavy appearance of the sMCL. Distal sMCL tears have a frequent association with concomitant knee injuries, especially ACL tears and lateral femorotibial osseous injuries. A SLL is particularly important to recognize because of implications for treatment.

Keywords Medial collateral ligament tear · Pes anserinus · Knee · MRI · Trauma

Introduction

The superficial medial collateral ligament (sMCL) is the largest ligament at the medial aspect of the knee [1] and is the primary static stabilizer against valgus stress [2, 3]. The sMCL and other medial knee stabilizers (i.e., the deep medial collateral ligament and the posterior oblique ligament) are often reported as the most commonly injured ligamentous structures

✉ Robert D. Boutin
boutin@stanford.edu

Russell C. Fritz
rfritzmd@gmail.com

Richard E. A. Walker
rewalker@ucalgary.ca

Mini N. Pathria
mpathria@ucsd.edu

Richard A. Marder
ramarder@ucdavis.edu

Lawrence Yao
lyao@cc.nih.gov

[1] Department of Radiology, Stanford University School of Medicine, 300 Pasteur Drive, Stanford, CA 94305-5105, USA

[2] Musculoskeletal Radiologist, National Orthopedic Imaging Associates, 1260 South Eliseo Drive, Greenbrae, Greenbrae, CA 94904, USA

[3] Department of Radiology, Cumming School of Medicine, McCaig Institute for Bone & Joint Health, University of Calgary, Room 812, North Tower, Foothills Medical Centre, 1403-29th Street NW, Calgary, AB T2N 2T9, Canada

[4] Department of Radiology, University of California San Diego Health System, 200 West Arbor Drive, San Diego, CA 92103-8756, USA

[5] Department of Orthopaedic Surgery, UC Davis School of Medicine, Sacramento, CA 95817, USA

[6] Radiology and Imaging Sciences, CC-NIH, 10 Center Drive, Bethesda, MD 20892, USA

Published online: 09 December 2019

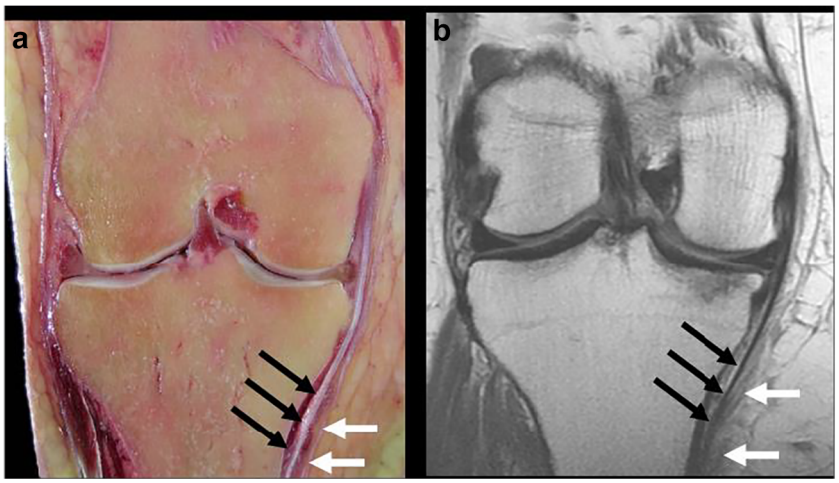

Fig. 1 Normal anatomy. **a** Coronal anatomic section shows the normal anatomy of the distal sMCL (black arrows) attachment to the tibia deep to the pes anserinus tendons (white arrows). **b** 39-year-old patient with a normal sMCL. A proton density coronal image reveals the normal distal attachment of the sMCL (black arrows), 5 cm distal to the joint line and deep to the pes anserinus tendons (white arrows)

of the knee [1, 4–7]. Clinically, these injuries are classified both by the structural severity (grade I, microscopic tear; grade II, partial tear; grade III, complete tear) and the degree of medial joint space widening caused by valgus stress (at 0 and 30° of knee flexion) [8, 9].

MRI is capable of detecting acute sMCL injuries [10], and the MRI grading of acute sMCL injuries has a very high degree of agreement with instrumented valgus-varus laxity testing [11]. Most sMCL injuries are located proximal to the joint line and heal with non-operative treatment.

Although sMCL sprains and isolated sMCL tears are usually treated non-operatively, surgery is commonly advocated when a complete sMCL tear occurs with other major ligament tears or when a distal sMCL tear is displaced [12–15]. Distal sMCL tears (at or near the tibial attachment) are increasingly recognized as an indication for surgery, because of a lower likelihood of anatomic ligament healing [12–15]. Undiagnosed distal sMCL ruptures can lead to chronic valgus instability as well as poorer outcomes for patients undergoing surgical

Table 1 Tabulation of MRI features and coexisting injuries associated with 51 distal sMCL tears, with and without a Stener-like lesion

	Stener-like lesion		No Stener-like lesion	
	n	%	*n*	%
Medial ligaments				
sMCL "wave sign"	18	90	21	68
Deep MCL tear	14	70	17	55
Cruciate ligaments				
Anterior cruciate ligament tear	18	90	24	77
Posterior cruciate ligament tear	4	20	7	23
Lateral ligaments				
Fibular collateral ligament tear	2	10	3	10
Posterolateral corner tear	4	20	4	13
Menisci				
Medial meniscus tear	7	35	11	35
Lateral meniscus tear	7	35	12	39
Osseous injury				
Medial—all***	15	75	13	42
Medial—fractures and osteochondral impactions	3	15	7	23
Lateral—all	19	95	29	94
Lateral—fractures and osteochondral impactions	11	55	16	52
Total	20		31	

sMCL superficial medial collateral ligament, *deep MCL* meniscofemoral and meniscotibial ligaments

***$p < 0.05$, Fisher's exact test

management of other injuries (e.g., failure of ACL reconstruction) [14]. Recent orthopedic literature has highlighted interest in optimizing a variety of surgical techniques for repair [12, 16–21] and reconstruction of the sMCL [22–28].

Compared with proximal sMCL tears, healing of distal sMCL ruptures may be impaired due to a relatively poor blood supply [14], less connection to adjacent soft tissue that can disperse traumatic loads [1, 2], or displacement of a torn sMCL stump from its anatomic insertion. In particular, some distal sMCL tears can displace superficial to the pes anserinus, as has been recognized in the radiology and orthopedic literature [13, 16, 19, 29–32]. Analogous to a Stener lesion in the thumb [33], this pattern of soft tissue interposition precludes normal healing of the displaced ligament stump back to bone and is an indication for surgery. This pattern of distal sMCL injury has been aptly recognized as a Stener-like lesion (SLL) of the sMCL [29, 30].

While the anatomy of the sMCL and pes anserinus is well known [1, 34–37] (Fig. 1), there is a paucity of radiologic literature on the MRI features of distal sMCL injuries that might influence surgical planning and patient management. The objective of this study was to analyze the MRI characteristics of distal sMCL tears and to seek distinguishing features of cases with a SLL.

Materials and methods

Patient cohort

This study was institutional review board approved and complied with Health Insurance Portability and Accountability Act (HIPAA) guidelines with exemption status for individual informed consent. A retrospective search was performed for MRI examinations of distal sMCL tears at four institutions obtained between January 2008 and December 2018. Cases were identified by searching the body and impression fields of knee MRI reports for terms including "distal MCL tear," "displaced MCL tear," "Stener lesion," and "knee dislocation," in addition to reviewing investigator teaching files. The inclusion criterion was an MRI examination that reported a sMCL tear centered distal to the joint line. All examinations were performed on 1.5-T or 3-T MRI scanners. Pulse sequences for evaluation included sagittal proton density, sagittal fat-suppressed fluid-sensitive, coronal proton density, coronal fat-suppressed fluid-sensitive, axial fat-suppressed fluid-sensitive, and axial proton density (or T2-weighted) series. (Eight cases of distal sMCL tears were excluded from analysis because five or more series were not available for review.) Slice thickness and interslice gap were 3.3 to 4 mm and 0.3 to 1 mm, respectively. Patient characteristics were recorded in each case, including age, sex, side of injury, and history of trauma.

MRI interpretation

All MRI examinations were assessed by consensus of two musculoskeletal radiologists with more than 20 years of subspecialty experience, using Horos viewing software (version 3.3.0). High-grade sMCL tears were diagnosed when fiber discontinuity was complete or essentially complete. We defined sMCL tears as "distal" when located inferior to the medial joint line. A SLL was recognized when the proximal stump margin of a sMCL tear was situated superficial to the pes tendons or sartorius fascia. The sMCL was scored as "wavy" if fibers had a serpentine morphology that has been described as the "wave sign" [13]. The horizontal position of the proximal sMCL stump was defined by the distance between the medial tibial cortex and the stump, measured along a line projected perpendicular to the medial tibial cortex, as depicted on coronal images. The vertical position of the proximal sMCL stump was defined by the vertical distance between the medial corner of the medial tibial plateau and the stump, as visualized on coronal images. These vertical and horizontal position metrics were defined ad hoc for purposes of this study analysis.

Coexisting knee injuries were scored as present or absent, including tears of the deep sMCL (either the medial meniscotibial ligament or the medial meniscofemoral ligament), anterior cruciate ligament (ACL), posterior cruciate ligament (PCL), fibular collateral ligament (FCL), posterolateral corner (not including the FCL), medial meniscus, and lateral meniscus. The posterior oblique ligament was not scored. Osseous injuries involving the medial vs. lateral femorotibial compartments were recorded, including contusions (defined as posttraumatic marrow edema), impaction injuries (defined as subtle impaction deformity in the subchondral bone plate), and frank fractures (defined as linear signal with interruption of the cortex). Osteochondral impaction injuries and fractures were also analyzed separately in a subgroup we defined as high-grade osseous injuries.

Statistical analysis

Descriptive statistics, including counts, standard deviation (sd), and percentages, were computed using PSPP software (version 1.20, GNU Free Software Foundation, www.gnu.org/s/pspp/). Comparison of group means was examined with the *t* test or Kruskal-Wallis test, while comparison of rates was examined with Fisher's exact test. A $p < 0.05$ was interpreted as significant.

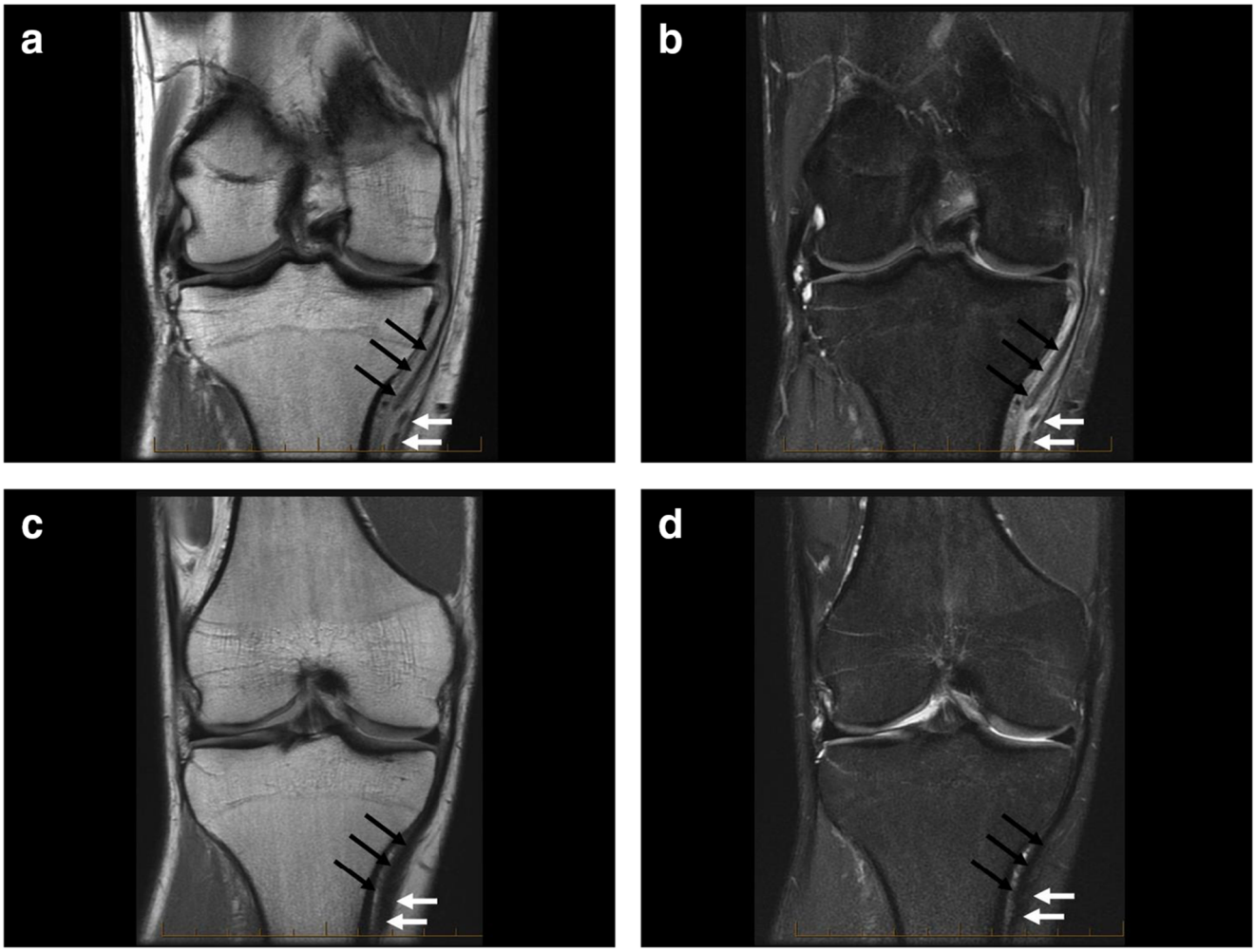

Fig. 2 22-year-old man with a distal sMCL tear, without Stener-like displacement on initial MRI; follow-up MRI at 4 months after conservative treatment reveals ligament healing. This corresponded to stability with valgus testing on physical examination. Proton density (**a**) and fat-suppressed T2-weighted (**b**) coronal images reveal tearing of the distal sMCL with the torn retracted ligament fibers (black arrows) remaining deep to the pes anserinus tendons (white arrows). Proton density (**c**) and fat-suppressed T2-weighted (**d**) coronal images 4 months later reveal interval healing with thickened distal sMCL fibers (black arrows) that remain deep to the pes anserinus tendons (white arrows)

Results

The study of distal sMCL tears included 51 patients (36 men, 15 women; mean age, 28 years (sd, 12); 18 left and 33 right knees). The mean age of patients with a SLL (26 years, sd, 8) was not significantly different than that of patients without a SLL (30 years, sd 14). All patients had a history of trauma.

MRI features of the distal sMCL tears and coexisting injuries are detailed in Table 1. Most tears (31/51) of the distal sMCL were non-displaced (Fig. 2). A SLL of the sMCL was identified in 20 of 51 (39%) cases (Fig. 3). Low-signal fibers of the sMCL had a wavy appearance (positive "wave sign") in 18/20 (90%) of cases with a SLL (Fig. 4) and in 21/31 (68%) of cases without a SLL; this difference did not reach significance ($p < 0.10$).

When the torn distal sMCL was displaced, the stump was located superficial to the pes anserinus. No distal sMCL tears were displaced into the joint. The proximal sMCL stump margin was located significantly ($p < 0.01$, Kruskal-Wallis) more distal in cases with a SLL (mean = 33 mm, sd = 11 mm) than in cases without a SLL (mean = 19 mm, sd = 16 mm), suggesting that a SLL was more likely to occur with more distal sMCL tears. The proximal sMCL stump margin was also located significantly ($p < 0.05$, Kruskal-Wallis) more medial in cases with a SLL (mean = 6.5 mm, sd = 2.5 mm), compared with cases without a SLL (mean = 4.8 mm, sd = 2.4 mm).

Distal sMCL tears were frequently accompanied by other soft tissue and osseous injuries. Of the cases with a SLL, only 2/20 (10%) occurred without associated tears of the ACL, PCL, or FCL; only 6/31 (19%) cases without SLL were

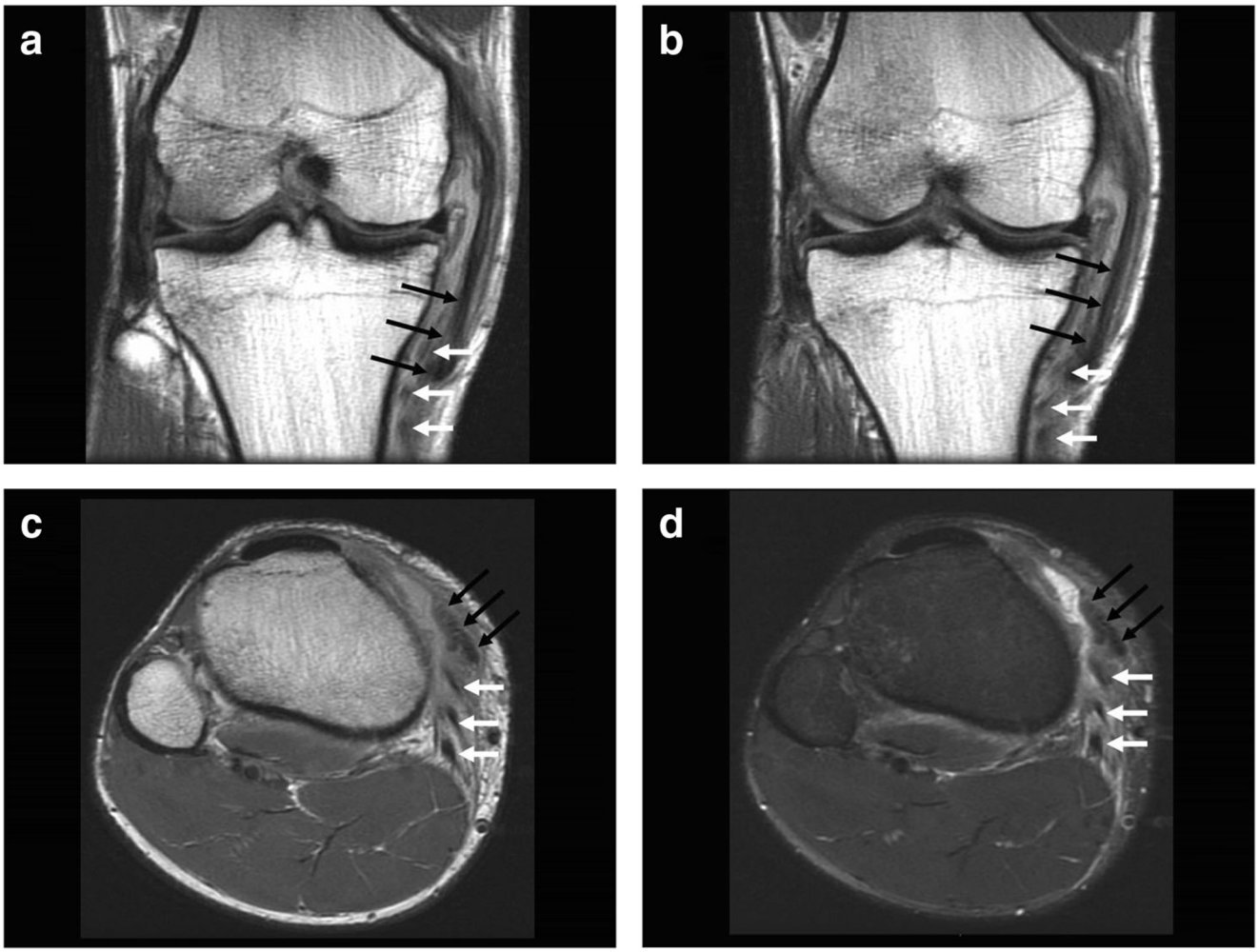

Fig. 3 55-year-old woman with a distal sMCL tear and Stener-like displacement of the torn ligament fibers. Proton density coronal (**a**, **b**) and proton density (**c**) and fat-suppressed T2-weighted (**d**) axial images reveal tearing of the distal sMCL, with the medially displaced torn fibers (black arrows) located superficial to the pes anserinus tendons (white arrows)

similarly "isolated." The frequencies of ACL tear, PCL tear, deep MCL tear, and lateral compartment osseous injury (90%, 20%, 70%, and 95%, respectively) in cases of SLL were not significantly different ($p > 0.10$) than the frequencies of these coexisting injuries in cases without a SLL (77%, 23%, 55%, and 94%, respectively). The frequency of medial compartment osseous injury (15/20, 75%) was significantly higher ($p < 0.05$, Fisher's exact test) in cases of a SLL, as compared with cases without a SLL (13/31, 42%).

Discussion

In this study of sMCL tears located distal to the medial joint line, the torn sMCL was displaced superficial to the pes anserinus in over one-third of cases. This can be a subtle finding and is important to recognize, as the interposed pes tendons preclude the sMCL from healing in an anatomic position, which can lead to chronic valgus instability of the knee. This SLL pattern of sMCL injury is an indication for early surgical repair with direct reattachment to the tibia, with or without augmentation [12, 16–21]. If the diagnosis is delayed, more extensive surgery may be needed, with reconstruction of the sMCL [22–28].

A SLL cannot be diagnosed reliably on clinical examination and is not visible by arthroscopy. Therefore, distal sMCL tears are important to recognize at MRI evaluation. Coronal images provided the best panoramic view of the distal sMCL and revealed a positive sMCL "wave sign" in 76% (39/51) of our patients that can be helpful in calling attention to the presence of a high-grade distal sMCL tear. Taketomi et al. [13] reported on 12 patients with distal sMCL tears that exhibited a "wave sign," both with and without a SLL. In our series, we found that the "waves" had a spectrum of shapes and

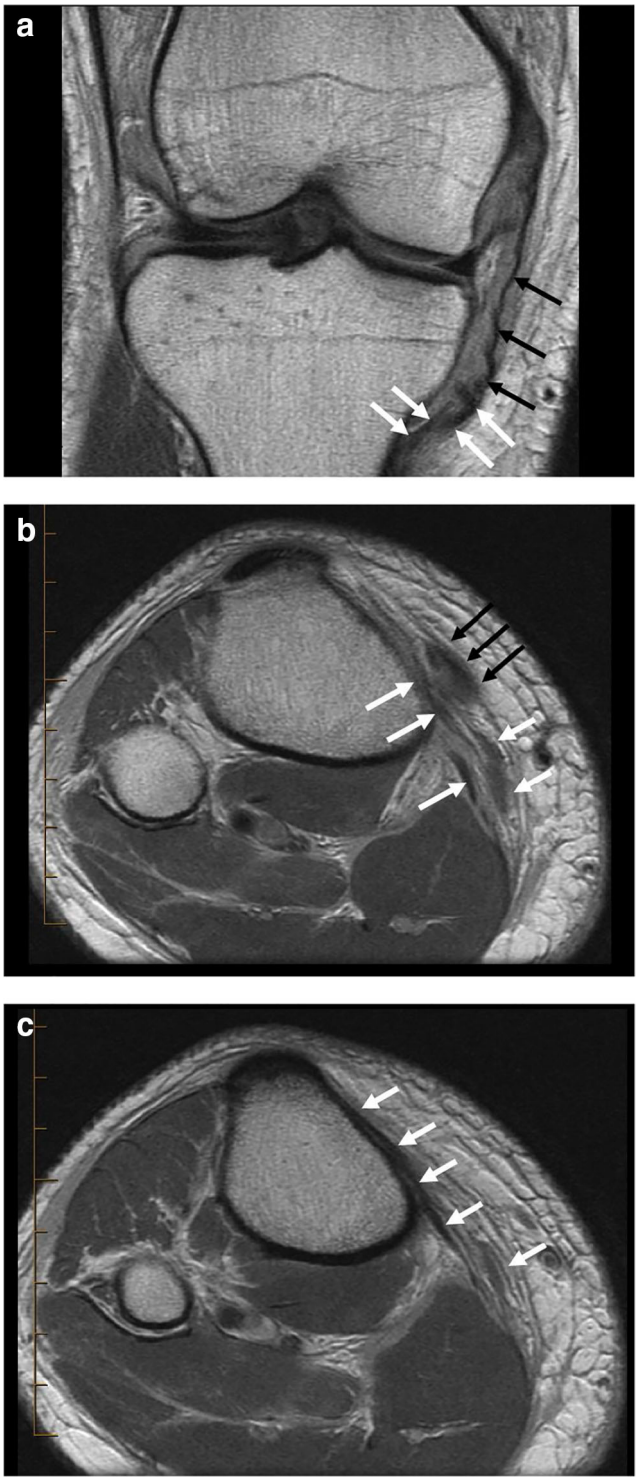

Fig. 4 48-year-old woman with a distal sMCL tear and Stener-like displacement of the torn ligament fibers. Proton density coronal image (**a**), proton density axial image (**b**), and further distal proton density axial image (**c**) reveal tearing of the distal sMCL with wavy fibers (black arrows) displaced superficial to the pes anserinus tendons (white arrows)

amplitudes (Fig. 5) and was more commonly seen in distal sMCL tears with SLL, than those without SLL, although this difference did not reach statistical significance. We did observe that the sMCL stump margin was located significantly more distal (relative to the medial tibial plateau) and more medial (relative to the medial tibial cortex) in cases with a SLL compared with cases without a SLL.

In our experience, axial images are often crucial in definitively showing whether the sMCL stump is situated deep (non-displaced) or superficial (displaced) to the pes anserinus. Although the diagnosis of a SLL on axial fat-suppressed T2-weighted images is generally straightforward, it is our impression that images *without* fat-suppression may be complementary in confirming a definitive diagnosis of a SLL by delineating the soft tissue planes around two thin anatomic structures—the distal sMCL and the distal sartorius (Fig. 6).

With both coronal and axial imaging, a serious potential pitfall is inadequate scan coverage or field of view that fails to encompass the distal sMCL attachment site on the tibia, which is located 5 [35] to 6 cm [1, 27, 37, 38] distal to the medial joint line. If an MRI exam does not include 5–6 cm distal to the medial joint line, the diagnosis of a SLL may be difficult or missed entirely. In such cases, we have found it may be necessary to call the patient back for additional imaging (Fig. 6). Although we did not study mechanism of injury for distal sMCL tears, Griffith et al. [39] found that with an applied valgus load, the distal sMCL (unlike the proximal sMCL) loading changes significantly with knee flexion and that the distal sMCL (compared with the proximal sMCL) experiences significantly greater loading at 60° of knee flexion. These authors also note that the proximal sMCL has broad connections with adjacent soft tissues that can mitigate loads, whereas a tensile force at the distal sMCL tends to be transferred to the tibial attachment site. Our study found that lateral osseous injuries were very frequent with sMCL tears, both with and without a SLL, but that medial osseous injuries were significantly more common in patients with a SLL (75%) than without a SLL (42%).

In the current study, distal sMCL tears were frequently accompanied by other knee injuries. For surgeons planning ligament reconstruction procedures, it is particularly important to note the high frequency of concomitant ACL tears (90% with a SLL vs. 77% without a SLL) and PCL tears (20% with a SLL vs. 23% without a SLL). The concomitant occurrence of cruciate ligament injuries is in line with the largest previous study [32] of distal sMCL tears in which 20 patients were reported; of these, 16 patients were found to have ACL injuries, 3 patients had combined ACL and PCL injuries, and only 1 had an isolated distal sMCL injury. All of those patients required surgery, and the authors concluded that failure to diagnose and repair distal sMCL tears acutely can adversely affect surgical options and adversely influence clinical and functional patient-reported outcomes.

We acknowledge the limitations of our study, including retrospective review of cases with a selection bias and lack of surgical follow-up. However, we believe that this study

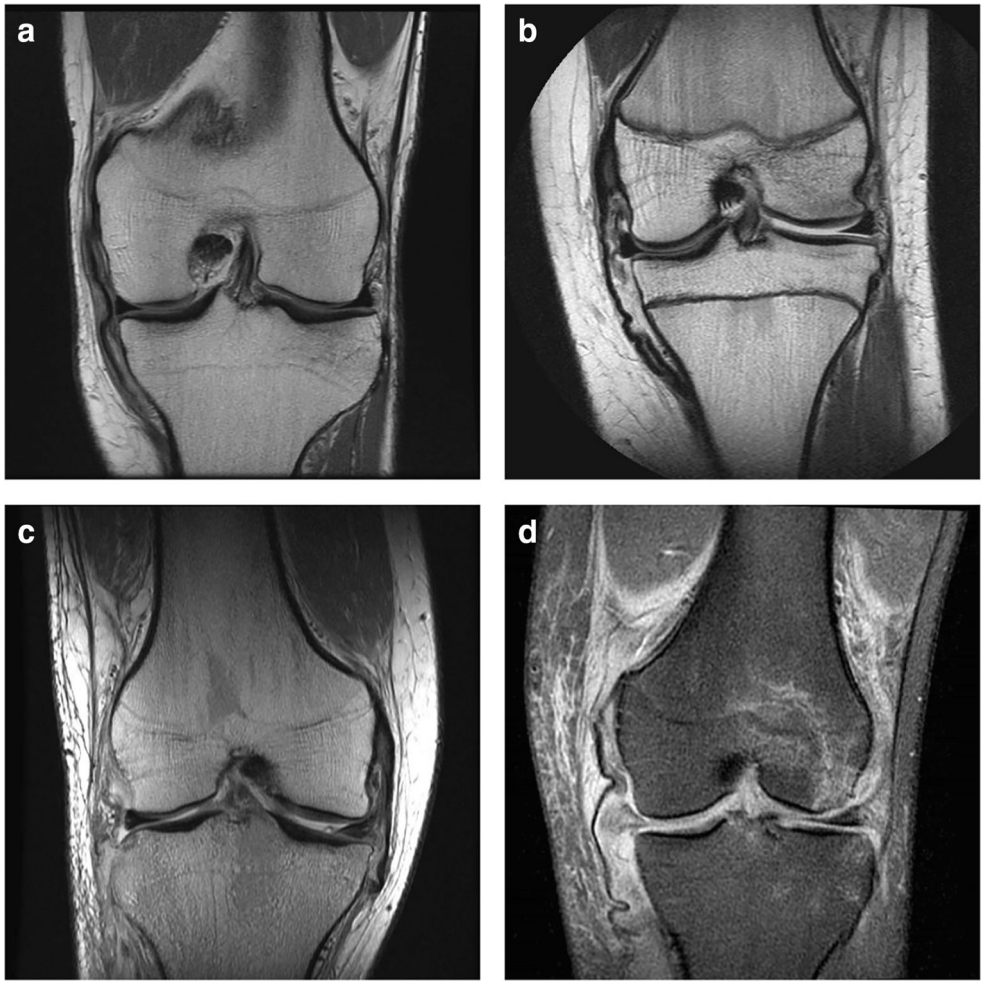

Fig. 5 Coronal images illustrating a spectrum of appearances for the "wave sign" seen with a distal tear of the sMCL, both *without* a Stener-like lesion (**a**) and *with* a Stener-like lesion (**b**–**d**)

should raise awareness and enhance diagnosis of a clinically important injury pattern. To our knowledge, this is the largest study comparing the MRI patterns of distal sMCL tears. Future research might address the possibility that these injuries are underdiagnosed on MRI, due to a low index of suspicion, satisfaction of search error (in the setting of multiple other derangements), lack of knowledge about sMCL tears occurring distally, or limitations in the field of view. Other studies can address issues that we did not, including injury prevalence, mechanism of injury, concomitant injuries of the posterior oblique ligament, optimal management, and long-term clinical outcome.

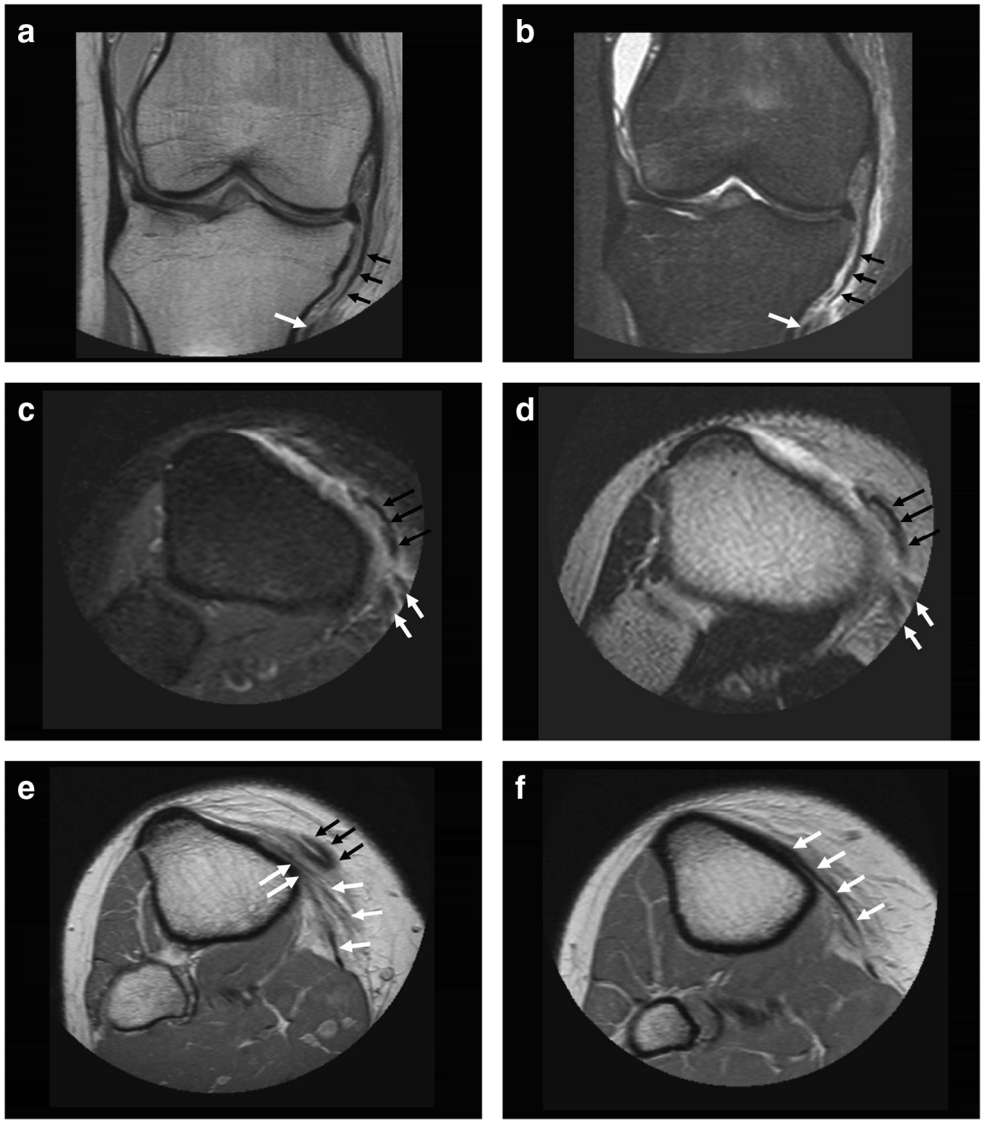

Fig. 6 34-year-old woman with a distal sMCL tear and Stener-like displacement of the torn ligament fibers. Proton density (**a**) and STIR (**b**) coronal images as well as STIR (**c**) and T2-weighted (**d**) axial images reveal tearing of the distal sMCL with equivocal displacement of the torn fibers (black arrows) superficial to the pes anserinus tendons (white arrows). The patient returned for additional proton density axial images (**e**, **f**) further distally that demonstrate definite medial displacement of the torn sMCL fibers (black arrows) superficial to the pes anserinus tendons (white arrows)

In conclusion, a high-grade distal sMCL tear should be considered when MRI depicts a wavy appearance to the sMCL. Distal sMCL tears are frequently accompanied by other serious knee injuries, especially ACL tears and lateral femorotibial osseous injuries. Regardless of concomitant injuries, a SLL of the distal sMCL is particularly important to

recognize because of its independent implications for treatment.

Compliance with ethical standards

Conflict of interest The authors declare that they have no conflicts of interest.

Ethical approval All procedures performed in studies involving human participants were in accordance with the ethical standards of the institutional and/or national research committee and with the 1964 Declaration of Helsinki and its later amendments or comparable ethical standards.

Informed consent Informed consent was waived for individual participants included in the study. The study was approved by the University of California Davis Institutional Review Board (IRB) and HIPAA-compliant.

References

1. LaPrade RF, Engebretsen AH, Ly TV, Johansen S, Wentorf FA, Engebretsen L. The anatomy of the medial part of the knee. J Bone Joint Surg Am. 2007;89(9):2000–10.
2. Griffith CJ, LaPrade RF, Johansen S, Armitage B, Wijdicks C, Engebretsen L. Medial knee injury: Part 1, static function of the individual components of the main medial knee structures. Am J Sports Med. 2009;37(9):1762–70.
3. Robinson JR, Bull AM, Thomas RR, Amis AA. The role of the medial collateral ligament and posteromedial capsule in controlling knee laxity. Am J Sports Med. 2006;34(11):1815–23.
4. LaPrade RF, Bernhardson AS, Griffith CJ, Macalena JA, Wijdicks CA. Correlation of valgus stress radiographs with medial knee ligament injuries: an in vitro biomechanical study. Am J Sports Med. 2010;38(2):330–8.
5. Wijdicks CA, Griffith CJ, Johansen S, Engebretsen L, LaPrade RF. Injuries to the medial collateral ligament and associated medial structures of the knee. J Bone Joint Surg Am. 2010;92(5):1266–80.
6. Memarzadeh A, Melton JT. Medial collateral ligament of the knee: anatomy, management and surgical techniques for reconstruction. Orthop Trauma. 2019;33(2):91–9.
7. Encinas-Ullán CA, Rodríguez-Merchán EC. Isolated medial collateral ligament tears: an update on management. EFORT Open Rev. 2018;3(7):398–407.
8. Hughston JC. The importance of the posterior oblique ligament in repairs of acute tears of the medial ligaments in knees with and without an associated rupture of the anterior cruciate ligament. Results of long-term follow-up. J Bone Joint Surg Am. 1994;76(9):1328–44.
9. Phisitkul P, James SL, Wolf BR, Amendola A. MCL injuries of the knee: current concepts review. Iowa Orthop J. 2006;26:77–90.
10. Yao L, Dungan D, Seeger LL. MR imaging of tibial collateral ligament injury: comparison with clinical examination. Skelet Radiol. 1994;23(7):521–4.
11. Rasenberg EI, Lemmens JA, van Kampen A, et al. Grading medial collateral ligament injury: comparison of MR imaging and instrumented valgus-varus laxity test-device. A prospective double-blind patient study. Eur J Radiol. 1995;21(1):18–24.
12. Trofa DP, Sonnenfeld JJ, Song DJ, Lynch TS. Distal knee medial collateral ligament repair with suture augmentation. Arthrosc Tech. 2018;7(9):e921–6.
13. Taketomi S, Uchiyama E, Nakagawa T, et al. Clinical features and injury patterns of medial collateral ligament tibial side avulsions: "wave sign" on magnetic resonance imaging is essential for diagnosis. Knee. 2014;21(6):1151–5.
14. Geeslin AG, Geeslin MG, LaPrade RF. Ligamentous reconstruction of the knee: what orthopaedic surgeons want radiologists to know. Semin Musculoskelet Radiol. 2017;21(2):75–88.
15. Azar FM. Surgical treatment of ACL/PCL/medial-side knee injuries. Operative Techniques in Sports Medicine. 2003;11(4):248–56.
16. DeLong JM, Waterman BR. Surgical repair of medial collateral ligament and posteromedial corner injuries of the knee: a systematic review. Arthroscopy. 2015;31(11):2249–55.
17. Forkel P, Flour J, Petersen W, Imhoff AB. Anatomical refixation of acute medial knee joint instability. Arthroscopy. 2017;30(1):28–31.
18. Golden T, Friedman AM, Jazayeri R, Sanderson B, Levy E. Primary repair of the medial collateral ligament with a double row suture technique and suture tape augmentation for acute tibial-sided injuries. Arthrosc Tech. 2019;8(4):e395–8.
19. Keyhani S, Mardani-Kivi M. Anatomical repair of Stener-like lesion of medial collateral ligament: a case series and technical note. Arch Bone Joint Surg. 2017;5(4):255–8.
20. van der List JP, DiFelice GS. Primary repair of the medial collateral ligament with internal bracing. Arthrosc Tech. 2017;6(4):e933–7.
21. Whelan D, Leiter J, Sasyniuk T, Litchfield R, Randle J, Hughes S, et al. Double-row repair of the distal attachment of the superficial medial collateral ligament: a basic science pilot study. Knee Surg Sports Traumatol Arthrosc. 2015;23(10):2820–4.
22. Coobs BR, Wijdicks CA, Armitage BM, Spiridonov SI, Westerhaus BD, Johansen S, et al. An in vitro analysis of an anatomical medial knee reconstruction. Am J Sports Med. 2010;38(2):339–47.
23. Kim MS, Koh IJ, In Y. Superficial and deep medial collateral ligament reconstruction for chronic medial instability of the knee. Arthrosc Tech. 2019;8(6):e549–54.
24. Kitamura N, Ogawa M, Kondo E, Kitayama S, Tohyama H, Yasuda K. A novel medial collateral ligament reconstruction procedure using semitendinosus tendon autograft in patients with multiligamentous knee injuries: clinical outcomes. Am J Sports Med. 2013;41(6):1274–81.
25. Liu X, Feng H, Zhang H, Hong L, Wang XS, Zhang J, et al. Surgical treatment of subacute and chronic valgus instability in multiligament-injured knees with superficial medial collateral ligament reconstruction using Achilles allografts: a quantitative analysis with a minimum 2-year follow-up. Am J Sports Med. 2013;41(5):1044–50.
26. Petersen W, Achtnich A. Reconstruction of the medial collateral ligament complex. Arthroscopy. 2017;30(1):38–43.
27. Prince MR, Blackman AJ, King AH, Stuart MJ, Levy BA. Open anatomic reconstruction of the medial collateral ligament and posteromedial corner. Arthrosc Tech. 2015;4(6):e885–90.
28. Van den Bogaerde JM, Shin E, Neu CP, Marder RA. The superficial medial collateral ligament reconstruction of the knee: effect of altering graft length on knee kinematics and stability. Knee Surg Sports Traumatol Arthrosc. 2011;19(Suppl 1):S60–8.
29. Boutin RD, Fritz RC. MRI of snow skiing and snowboarding injuries. Semin Musculoskelet Radiol. 2005;9(4):360–78.
30. Corten K, Hoser C, Fink C, Bellemans J. Case reports: a Stener-like lesion of the medial collateral ligament of the knee. Clin Orthop Relat Res. 2010;468(1):289–93.
31. Marchant MH Jr, Tibor LM, Sekiya JK, Hardaker WT Jr, Garrett WE Jr, Taylor DC. Management of medial-sided knee injuries, part 1: medial collateral ligament. Am J Sports Med. 2011;39(5):1102–13.
32. Desai VS, Wu IT, Camp CL, Levy BA, Stuart MJ, Krych AJ. Midterm outcomes following acute repair of grade III distal MCL avulsions in multiligamentous knee injuries. J Knee Surg. 2019 May 8. [epub PMID: 31067586]

33. Stener B. Displacement of the ruptured ulnar collateral ligament of the metacarpo-phalangeal joint of the thumb. J Bone Joint Surg. 1962;44B(4):869–79.
34. LaPrade RF, Moulton SG, Nitri M, Mueller W, Engebretsen L. Clinically relevant anatomy and what anatomic reconstruction means. Knee Surg Sports Traumatol Arthrosc. 2015;23(10):2950–9.
35. Saigo T, Tajima G, Kikuchi S, et al. Morphology of the insertions of the superficial medial collateral ligament and posterior oblique ligament using 3-dimensional computed tomography: a cadaveric study. Arthroscopy. 2017;33(2):400–7.
36. Curtis BR, Huang BK, Pathria MN, Resnick DL, Smitaman E. Pes anserinus: anatomy and pathology of native and harvested tendons. AJR Am J Roentgenol. 2019;30:1–10. https://doi.org/10.2214/AJR.19.21315 Epub ahead of print; PubMed PMID: 31361527.
37. Laprade RF, Wijdicks CA. Surgical technique: development of an anatomic medial knee reconstruction. Clin Orthop Relat Res. 2012;470(3):806–14.
38. Liu F, Yue B, Gadikota HR, et al. Morphology of the medial collateral ligament of the knee. J Orthop Surg Res. 2010;5:69.
39. Griffith CJ, Wijdicks CA, LaPrade RF, Armitage BM, Johansen S, Engebretsen L. Force measurements on the posterior oblique ligament and superficial medial collateral ligament proximal and distal divisions to applied loads. Am J Sports Med. 2009;37(1):140–8.